

# Regional Veterinary Laboratories Report

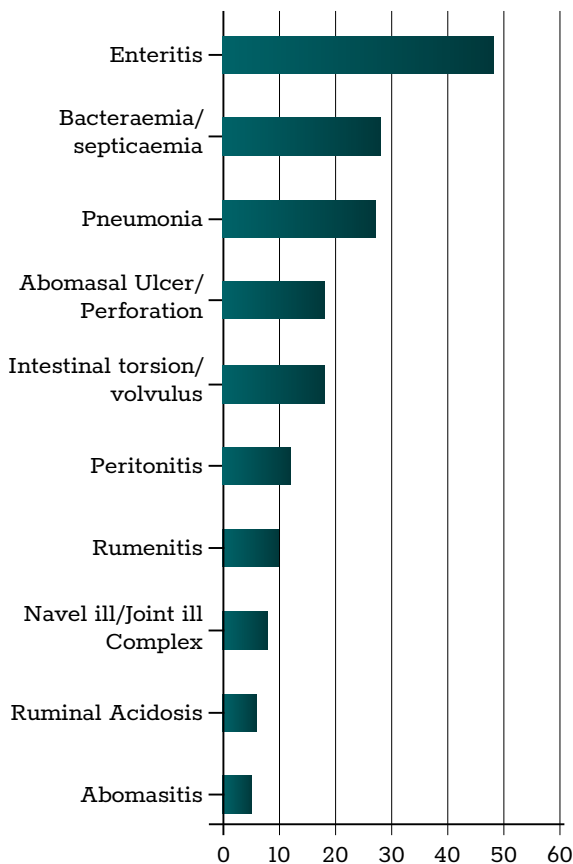
March 2022

Regional Veterinary Laboratories (RVLs) carried out necropsy examinations on 586 carcasses and 263 fetuses during March 2022. Additionally, 2,082 diagnostic samples were tested to assist private veterinary practitioners with the diagnosis and control of disease in food producing animals. This report describes a selection of cases investigated by the Department of Agriculture, Food and the Marine's (DAFM) veterinary laboratories in March 2022.

The objective of this report is to provide feedback to veterinary practitioners on the pattern of disease syndromes at this time of the year by describing common and highlighting unusual cases. Moreover, we aim to assist with future diagnoses, encourage thorough investigations of clinical cases, highlight available laboratory diagnostic tools and provide a better context for practitioners when interpreting laboratory reports.

## CATTLE

Pneumonia and bacteraemia/septicaemia were the most common diagnoses from necropsy in cattle in the RVLs during March 2022.

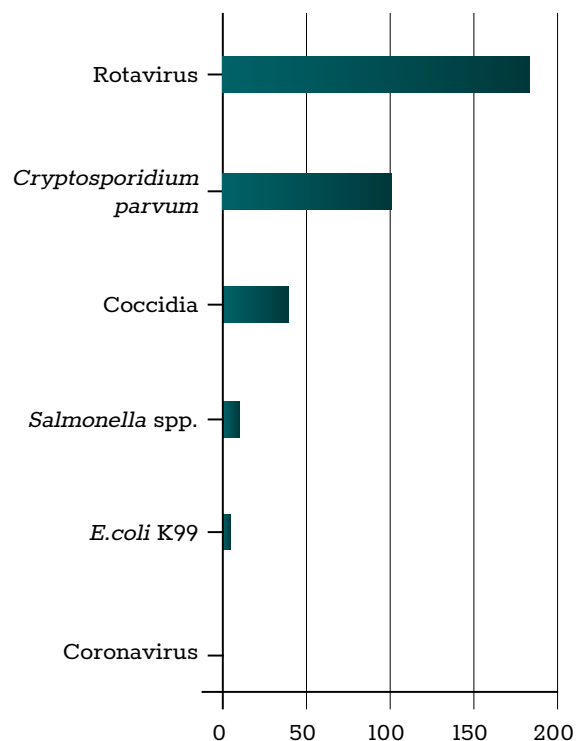


**Table 1: The most common diagnoses in cattle submitted for necropsy in March 2022.**

## GASTROINTESTINAL TRACT

### Enteritis

Enteritis was the most common diagnosis in calves in March 2022. Following a similar pattern to most springs, rotavirus and *Cryptosporidium parvum* were the most commonly detected enteric pathogens in younger calves, while coccidia (*Eimeria* spp.) were the most commonly detected pathogens in older calves.

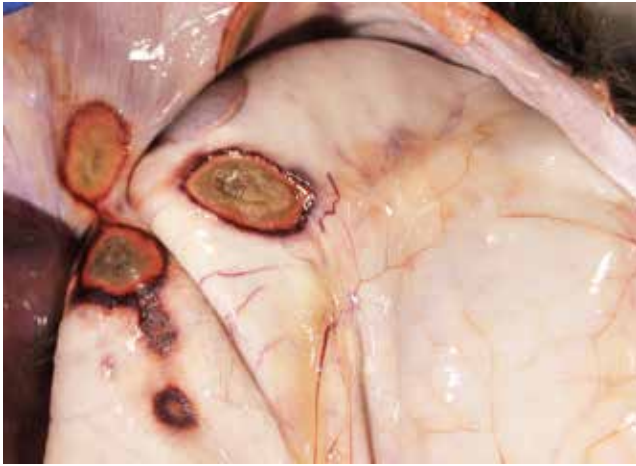

**Table 2: The most common enteric pathogens in calves in March 2022.**

### Cryptosporidiosis and mycotic rumenitis

Athlone RVL examined two three-week-old calves with a history of inappetence, weakness and diarrhoea. There had been no response to treatment. On gross post-mortem examination, there were similar findings in both calves examined. There was moderate dehydration. The rumen contained copious milk with a sour acidic odour. The rumen mucosa was diffusely thickened, 'leathery' and haemorrhagic with multifocal necrotising ulcers of varying size and depth including full thickness. The intestinal contents were fluid. A sample of rumen contents was collected from both calves; the rumen pH values were low at 4.8 and 4.9 (normal rumen pH is 5.5 – 7.0; values under 5.5 are considered indicative of acidosis). *Candida* sp. was isolated from the rumen wall. A faecal sample was collected from both calves; both had a heavy *C. parvum* infection. On histopathological

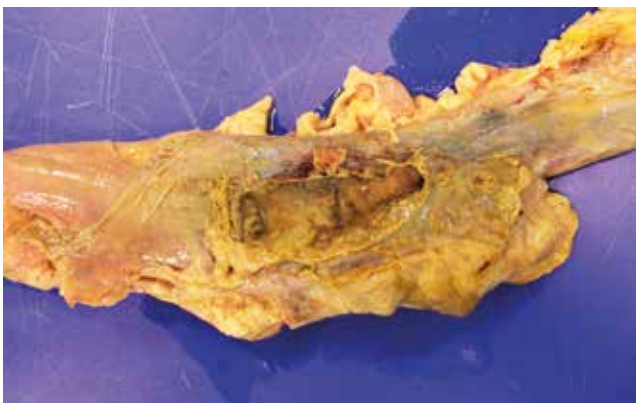
examination, there was a severe, subacute, multifocal, neutrophilic rumenitis with intralesional fungal hyphae; these findings were consistent with fungal rumenitis. A diagnosis of cryptosporidiosis and fungal rumenitis was made. The rumenitis was most likely secondary to the cryptosporidiosis.



**Figure 1: Full-thickness necrotising ulcers in the rumen wall in a calf with a fungal rumenitis. Photo: Sarah Delaney.**

#### Perforated colon

Athlone RVL examined a two-year-old bullock with a history of sudden onset weakness, constipation, and passing foul-smelling faeces. There had been no response to treatment. On gross post-mortem examination, there was mild to moderate dehydration. The mucous membranes were congested. There was a severe, diffuse, fibrinous peritonitis with abundant yellow fluid and large fibrin clots in the peritoneal cavity. There was a focal, necrotising perforation of the proximal colon approximately 5cm in diameter, with leakage of intestinal contents into the peritoneal cavity. On culture, *Escherichia coli* was isolated from the spleen. A diagnosis of perforated colon and peritonitis was made.



**Figure 2: A perforation in the colon wall which led to the development of peritonitis in a bullock. Photo: Sarah Delaney.**

#### Salmonellosis

Limerick RVL received a faecal sample from a dairy cow in a 130-cow herd. The history was of high temperature and diarrhoea in at least seven cows, some of which had aborted. Herd had been vaccinated for *Salmonella* spp. and a booster had been given five weeks previously. *Salmonella enteritidis* was isolated from the sample by culture. Serotyping carried

out in the central veterinary research laboratory (CVRL) Backweston confirmed it to be *Salmonella* Bovismorbificans. This has been associated with enteritis and septicaemia in cattle. The same *Salmonella* serotype was isolated from a bovine faecal sample submitted to Kilkenny RVL in January 2022. The history was similar and *Salmonella* vaccination was also being carried out in that herd. *Salmonella* vaccines available in Ireland are effective against *Salmonella* Dublin and *Salmonella* Typhimurium.

#### Intestinal torsion/volvulus

A four-week-old calf was submitted to Kilkenny RVL with a history of rapidly deteriorating prior to death. On examination, the calf was severely dehydrated. There were fibrin strands multifocally in the abdominal cavity. There was a torsion of the small intestine, and the intestinal content was bloody. *E. coli* was cultured from multiple organs indicating a bacteraemia. The rumen content was porridge-like in consistency, but the pH was within normal limits. However, the calf was autolysed, and ruminal pH increases after death so the possibility of a previous acidosis could not be excluded. *Clostridium perfringens* alpha toxin was identified. The significance of identifying alpha toxin in isolation is difficult to interpret, as *C. perfringens* type A strains which produce this toxin can be present in the normal intestinal microbiota; isolation of this toxin type is not diagnostic for disease. A review of vaccination protocols was advised however, with the use of a multivalent clostridial vaccine recommended.

Athlone RVL examined a six-week-old calf with a history of sudden death. The abdomen was distended and there was an intestinal torsion with purple-coloured intestines distended with gas and haemorrhagic contents. Ruminal contents were soft and had an acidic smell. The rumen pH was below the normal range at 4.9 and indicative of a ruminal acidosis which may predispose to intestinal torsions. A conclusion of death due to an intestinal torsion was made and the owner was advised to review concentrate inclusion rates in the diet.

#### Abomasal torsion

A four-month-old calf was submitted to Limerick RVL with a history of sudden death. Necropsy disclosed a 360-degree torsion of the abomasum, which had become fluid-filled and necrotic. A diagnosis of abomasal torsion was made.

### RESPIRATORY TRACT

#### Pneumonia

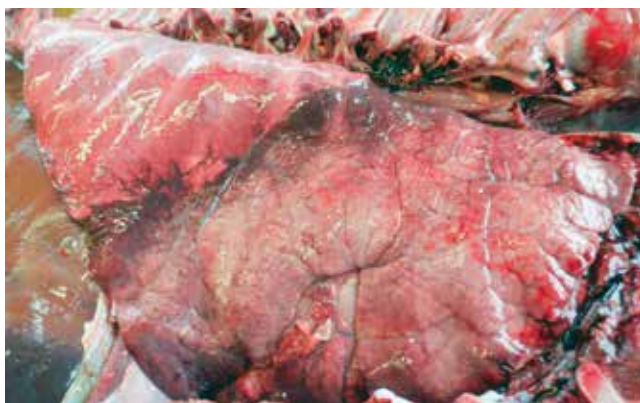A nine-month-old weanling with a history of ill-thrift was submitted to Kilkenny RVL having failed to respond to treatment with antibiotics. On examination of the carcass, there was marked dehydration. Approximately 70 per cent of the pulmonary tissue was abnormal, the lungs were overinflated with multifocal 'ground glass' emphysema. There were no adult lungworms visible. There was cranioventral consolidation affecting approximately 30 per cent of the lungs. There was mild enlargement of the bronchial lymph nodes. There were some suspect parasitic structures in the cecum content (later identified as *Trichuris*). *Trueperella pyogenes* was

cultured from the lung, viral and bacterial polymerase chain reaction (PCR) tests were negative. Histopathology showed a severe, subacute, broncho-interstitial pneumonia with hyperplasia of type 2 pneumocytes, and visible eosinophils. Differential diagnoses for the changes seen included viral and parasitic pneumonia (fog fever was considered but is less likely given the time of year and the age of the animal). Submission of additional samples was recommended from cohorts.



**Figure 3: 'Ground glass' emphysema in the lung of a weanling with broncho-interstitial pneumonia. Photo: Aideen Kennedy.**

A four-week-old calf that was 'off form' before death was submitted to Kilkenny RVL. On necropsy, there was a hyperaemic tracheal mucosa. Approximately 70 per cent of the pulmonary tissue was consolidated in a cranioventral distribution. There were small areas of abscessation within the consolidated region. *Mannheimia haemolytica* was cultured from multiple organs suggesting a bacteraemia. Multiple agents were identified by PCR including *M. haemolytica*, *Histophilus somni* and bovine respiratory syncytial virus (BRSV). A review of respiratory disease control was recommended.

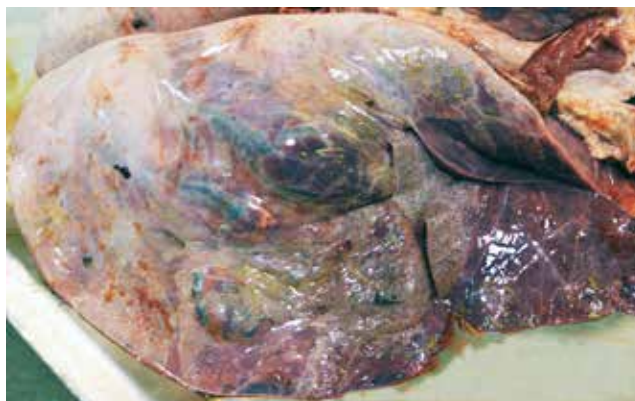

**Figure 4: Cranioventrally distributed pneumonia in a calf from which multiple pathogens were identified. Photo: Aideen Kennedy.**

### Infectious bovine rhinotracheitis

Athlone RVL examined two weanlings that had been purchased four weeks previously and vaccinated against infectious bovine rhinotracheitis (IBR) at that time. They presented with respiratory signs two weeks later, and were treated, but didn't respond, and died. An underlying

parasitic bronchitis issue was suspected. Both animals were found to have a severe haemorrhagic membrane along the entire length of the trachea. There was bilateral cranioventral pulmonary consolidation with multifocal areas of necrosis on cross section, and fibrinous pleurisy and caudo-dorsal subpleural and interlobular emphysema and bullae. PCR testing returned a strong positive result for bovine herpesvirus 1 (BHV-1), the causative organism of IBR, and *Mycoplasma bovis* in both animals; *Pasteurella multocida* and *M. haemolytica* were detected by PCR also. The histopathological findings within the trachea were consistent with IBR, additionally changes within the distal airways might be consistent with *Mycoplasma bovis* infection, and the presence of large infarcts were suggestive of *Pasteurellaceae* involvement. A diagnosis of tracheitis and pneumonia was made with BHV-1 (IBR), *Mycoplasma bovis* and *Pasteurella spp* detected.



**Figure 5: Subpleural bullae, air-filled spaces within the lung which developed because of emphysematous destruction of the lung parenchyma. Photo: Denise Murphy.**

Sligo RVL examined the carcass of a 13-month-old heifer which had been observed with severe dyspnoea and deterioration despite treatment efforts. It was the fourth death in the group which consisted of bought-in animals from various sources. On post-mortem examination, the carcass presented with necrotic tracheitis and bronchopneumonia with a foul-smelling pleural exudate. BHV-1 and parainfluenza-3 (PI3) were detected in the lesions by PCR. IBR due to BHV-1 was diagnosed as the most likely cause of death.

## NERVOUS SYSTEM

### Botulism

A nine-year-old suckler cow was submitted to Limerick RVL with a history of drooling from its mouth and an inability to chew properly, and its tongue protruding from its mouth. The cow was moved to a paddock but became recumbent and was unable to rise and died. Bovine botulism was suspected. This was the fourth death from a herd of 33 within 10 days. Cows were housed on a diet of silage only. A dead cat had been found in a silage bale four days before this animal displayed clinical signs. On necropsy, there were a number of what were deemed to be incidental findings, such as pulmonary oedema, and thickening of the bile ducts in the liver, suggestive of chronic fluke infection. Intestinal contents

were watery in consistency and no gross lesions were seen in the oral cavity. No significant bacterial pathogens were isolated on routine culture of liver, lung and brain. Renal cortical lead assay proved negative. Samples of rumen, abomasum, small and large intestinal contents were sent to the Agri-Food and Biosciences Institute (AFBI) in Stormont for botulism testing. All samples were positive for *Clostridium botulinum* C/D toxin. A diagnosis of bovine botulism was made, and the local Regional Veterinary Office was notified.

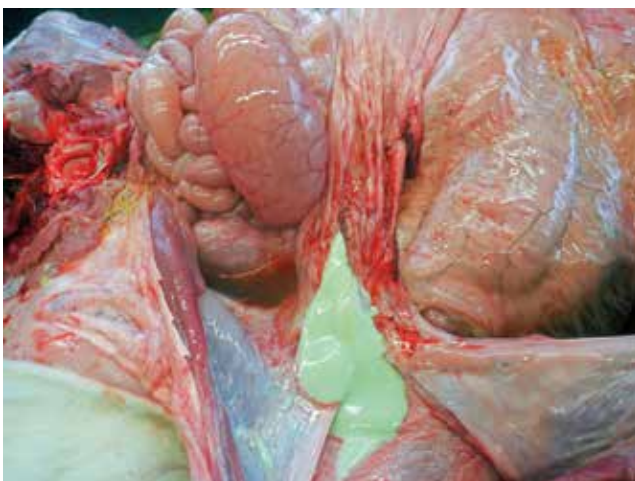

**Figure 6: The decomposed remains of a dead cat found in a bale of silage, on a farm where botulism was subsequently diagnosed in silage-fed cows. Photo: John Underhill.**

## MUSCULOSKELETAL

### Omphalophlebitis

A 39-day-old calf found dead with no previous signs was submitted to Kilkenny RVL. It was the third case in the herd. On necropsy, there was ascites with fluid in the abdomen. There was marked abscessation of the navel with the abscess containing approximately 30ml of pus. There was moderate oedema in the rumen wall. The mucosal surface was very hyperaemic; there was a mixture of roughage and milk, suggesting ruminal drinking. The intestinal contents were fluid and yellow. The liver was rounded and there were multifocal pale pinpoint lesions on the kidneys. *E. coli* was cultured from multiple organs indicating a bacteraemia. A review of umbilical hygiene at calving was recommended.



**Figure 7: Pus from an umbilical abscess in a calf. Photo: Aideen Kennedy.**

### Terminal dry gangrene

Sligo diagnosed bacteraemia with terminal dry gangrene due to infection with *Salmonella* Dublin in a two-month-old dairy calf that had a history of chronic and progressive illness over a period of several weeks. This manifestation of Salmonellosis is rare but has been reported in particular in winter months in younger animals. Cold agglutinins (often immunoglobulin M class autoantibodies which are activated by the cold) bind to red corpuscles and cause ischaemia of the distal extremities by blocking smaller blood vessels. Often the tips of the ears and the tip of the tail are affected as well, becoming dry and papery as the disease progresses.

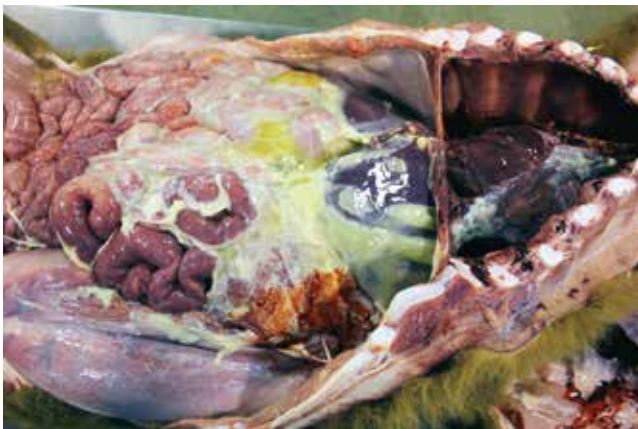

**Figure 8: Terminal dry gangrene of the extremities associated with *Salmonella* Dublin infection in a calf. Photo: Colm Ó Muireagain.**

## MISCELLANEOUS

### Polyserositis

Athlone RVL examined a two-month-old calf with a history of sudden death. There had been one other similar loss in the herd. On gross post-mortem examination, there was moderate dehydration. There was a marked, diffuse, fibrinous peritonitis which was more severe in the cranial peritoneal cavity, and a marked, multifocal, fibrinous pleuritis and pericarditis. *M. haemolytica* was isolated from the lung and liver. A diagnosis of polyserositis (pericarditis, pleuritis, peritonitis) was made.



**Figure 9: Fibrinous peritonitis and pleuritis in a calf from which *M. haemolytica* was cultured. Photo: Sarah Delaney.**

**Black Disease**

A one-year-old heifer with a history of sudden onset anorexia, followed by recumbency, was examined by Sligo RVL. On necropsy, there was fibrinous pleuritis and peritonitis. There were multifocal haemorrhages on the serosal surface of several abdominal organs. On the liver, there was a focal area of necrosis approximately 2cm in size surrounded by a hyperaemic rim. *Clostridium novyi* was detected by fluorescent antibody technique (FAT) from the lesion. Black disease was diagnosed as the cause of death.

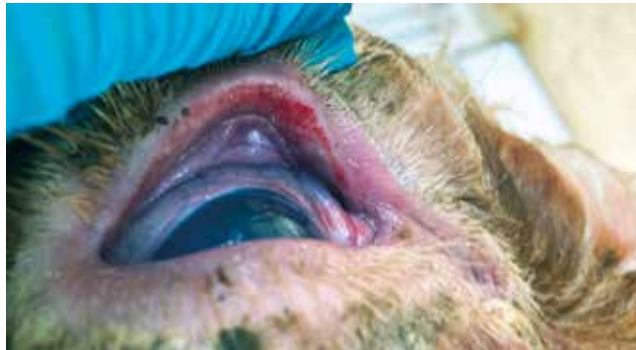

**Figure 10: Pathognomonic pale area of necrosis with hyperaemic rim on a liver in a case of black disease in a heifer. Typical lesion with characteristic significant reddening of abdominal serosal membranes. Photo: Shane McGettrick.**

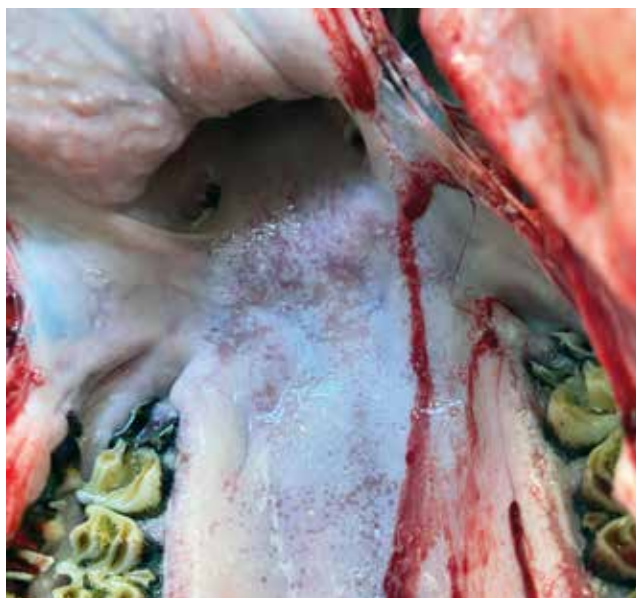**Malignant catarrhal fever**

Sligo RVL diagnosed malignant catarrhal fever in a one-year-old heifer. The animal had been noticed two months prior to death as it developed blindness, anorexia and further physical decline. The animal appeared always restless and in pain. On post-mortem examination, there was severe, focally extensive ulceration present on the lips covered by a sero-cellular crust. A sero-cellular crust was also present on the eyelids. There were multifocal erosions present on the distal pharyngeal mucosa. The retropharyngeal lymph nodes were enlarged and purulent. There were multifocal haemorrhagic cysts approximately 5-10mm in size on the aortal arch as well as multifocal haemorrhages on the epicardium. There was focally extensive haemorrhage on the meninges over left caudal cerebrum. The meninges were diffusely cloudy. Ovine herpesvirus 2 (OHV-2), the causative organism of malignant catarrhal fever in cattle, was detected by PCR. A clinical

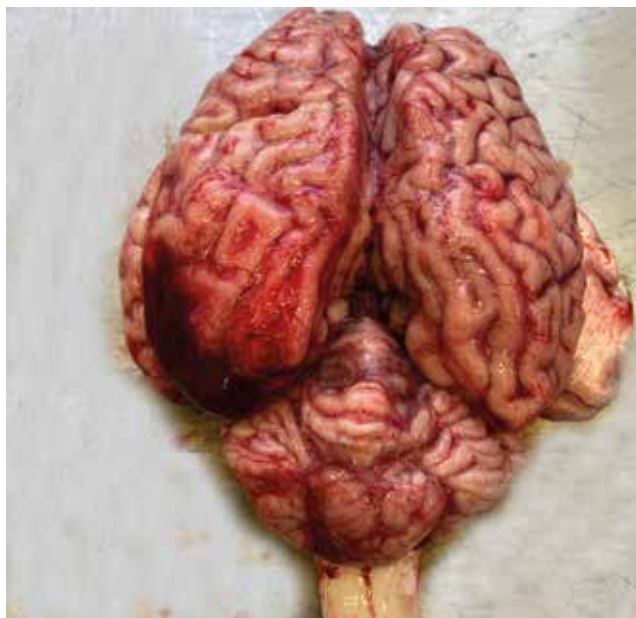
history of two months is relatively unusual for this disease as deaths tend to occur in the acute stages, but chronic disease has been previously documented.



**Figure 11: Sero-cellular crust on the inner eyelids. Photo: Shane McGettrick.**



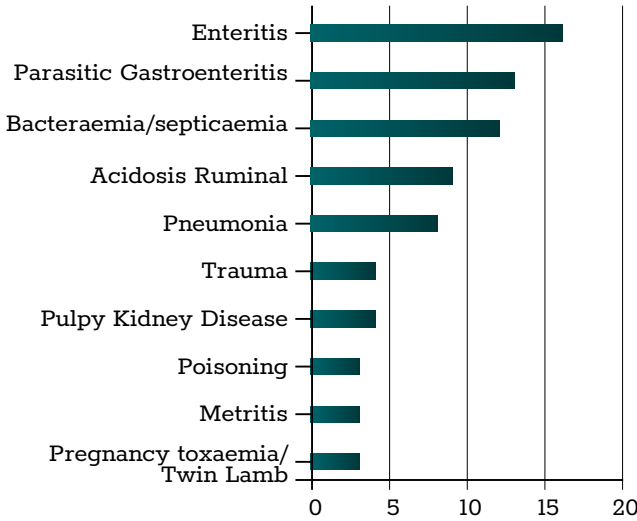
**Figure 12: Multifocal erosions on the distal pharyngeal mucosa. Photo: Shane McGettrick.**



**Figure 13: Focally extensive haemorrhage of left caudal cerebrum. Photo: Shane McGettrick.**

**SHEEP**

Enteritis and parasitic gastroenteritis were the most common diagnoses from necropsy in sheep in the RVLs during March 2022.

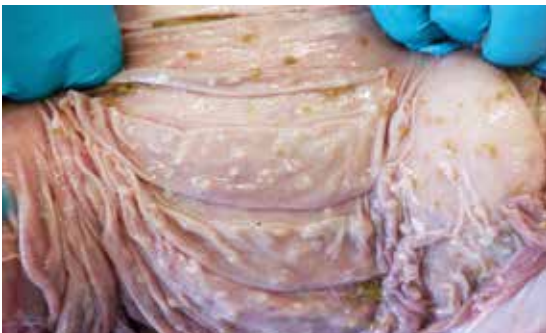

**Table 3: The most common diagnoses in sheep submitted for necropsy in March 2022.**

**GASTROINTESTINAL TRACT**

**Parasitic gastroenteritis**

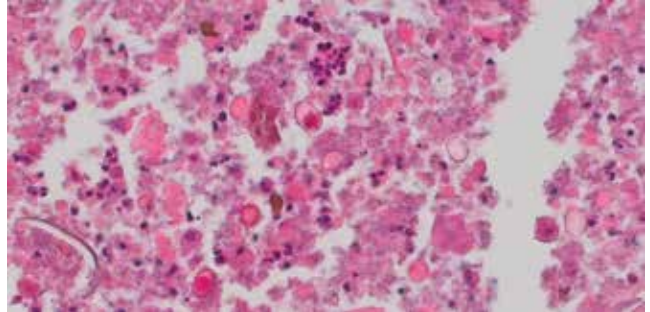
A five-year-old ram with a history of anaemia and weight loss was submitted to Kilkenny RVL. Others in group had similar signs. A previous ram from this group submitted to Kilkenny had pneumonia and a high parasite burden. Examination showed multifocal firm white lesions ranging in size from pinpoint to 0.5cm approximately; these foci were visible from both the mucosal and serosa surface of the abomasum. Similar firm pinpoint white foci extended along the small and large intestines. The rectal contents were of normal consistency. McMaster test results showed low egg counts. On histopathology, there were multifocal parasitic granulomas in the intestine. Sections of the abomasum showed numerous parasitic nodules in the mucosa and submucosa, and one nematode structure was present in the mucosa surrounded by lymphocytes. The differential diagnoses for abomasal nematodes include: *Haemonchus*, *Ostertagia/Teladorsagia* and *Trichostrongylus* spp. Although the egg count was low in this animal, a review of parasite control on farm was recommended as history indicated others in the flock with weight loss. Submission of faecal samples was recommended from affected cohorts.



**Figure 14: Multifocal white lesions in the abomasum of a ram, determined on histopathology to be parasitic in origin. Photo: Aideen Kennedy.**

**Coccidiosis**

A six-week-old lamb was submitted to Kilkenny RVL with a history of diarrhoea. On gross post-mortem examination, the lungs were congested, there was moderate fill in the rumen, and there was no milk clot in the abomasum, which can be suggestive of a period of inappetence. There were semi-solid contents in the small and large intestines. A severe infection with coccidial oocysts was detected on faecal examination. A severe enteritis with intra-lesional coccidial structures was diagnosed on histopathology. A review of coccidiosis control was recommended.



**Figure 15: Coccidial life stages in the intestinal wall of a lamb. Photo: Maresa Sheehan.**

**Rumen acidosis**

Athlone RVL examined a five-year-old ewe with a history of diarrhoea following a recent change of diet. There had been two other similar losses in the flock. On gross post-mortem examination, the rumen contents were loose and were of 'porridge-like' consistency with a significant quantity of grain and a strong acidic smell. The intestinal contents were fluid, in particular the small intestinal contents, and the mesenteric vessels were injected. A sample of the ruminal contents was collected, the pH of which was 4.6. Rumen pH values <5 are highly suggestive of ruminal acidosis and pH values rise post-mortem. On histopathology, there was a neutrophilic, acute, multifocal rumenitis with oedema and hyperkeratosis. These changes were most likely attributed to the acidosis. A diagnosis of ruminal acidosis/grain overload was made, and a review of the diet of cohorts was recommended. A sudden increase in the amount of carbohydrate ingested is more important than the actual amount. Sudden temperature changes, e.g., hot or cold weather, may result in temporary reductions in feed consumption, and acidosis may develop once animals return to full feed.

**RESPIRATORY TRACT**

**Pneumonia and Septicaemia**

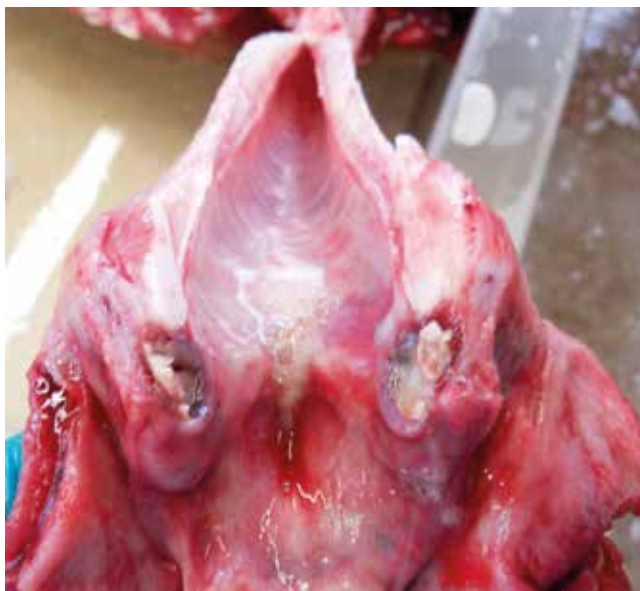Sligo RVL examined the carcass of a three-year-old ewe with a history of being 'off form' for two to three days before death. It was the second death within a few days in the flock, and two further sheep appeared sick. On necropsy, there was a large amount of froth in the airways and the lungs were oedematous and heavy with multifocal areas of consolidation. *Listeria monocytogenes* was isolated from the pulmonary tissue and was considered likely to be highly significant. *Listeria* septicaemia is an occasional cause of death in sheep. It is

## I REGIONAL VETERINARY LABORATORIES REPORT

associated with similar risk factors to listerial meningitis, i.e., soil contamination of feed and silage feeding.

### Laryngeal chondritis

A six-week-old lamb was found dead with no prior signs observed and submitted to Kilkenny. On necropsy, there was bilateral abscessation of the arytenoid cartilage, or laryngeal chondritis. The lungs were congested. The intestinal content was very liquid, the walls however were autolysed. *P. multocida* was cultured on multiple organs indicating a bacteraemia. *Mycoplasma ovipneumoniae* PCR positive results were also obtained. Histopathology showed multifocal, suppurative bronchopneumonia with bacterial colonies visible. In the liver, there were multifocal areas of hepatic necrosis with findings suggestive of gram-negative septicaemia. It was believed that the bacteraemia/pneumonia probably occurred subsequent to the laryngeal chondritis.



**Figure 16: Bilateral abscessation of the arytenoid cartilage, typically seen in cases of laryngeal chondritis. Photo: Aideen Kennedy.**

### Ovine Pulmonary Adenomatosis

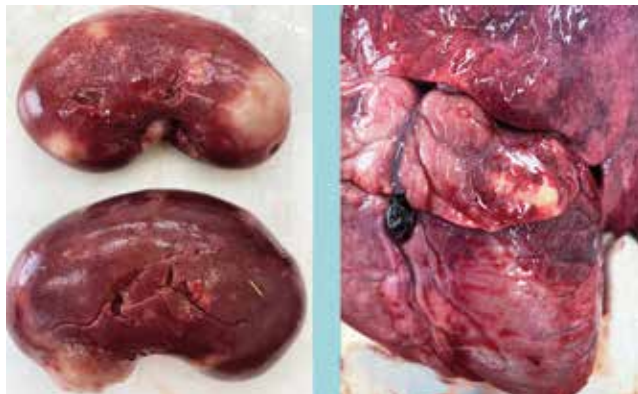Sligo RVL diagnosed Jaagsiekte, or ovine pulmonary adenocarcinoma, in a three-year-old ram. The animal had presented with dyspnoea without improvement on treatment. On necropsy, there was bilateral consolidative pneumonia. *P. multocida* and *M. ovipneumoniae* were isolated from the lesions. Ribonucleic acid (RNA) specific to Jaagsiekte sheep retrovirus, the causative organism, was detected in the lesions by PCR technique.

## URINARY/REPRODUCTIVE TRACT CARDIOVASCULAR SYSTEM

### Abscessation

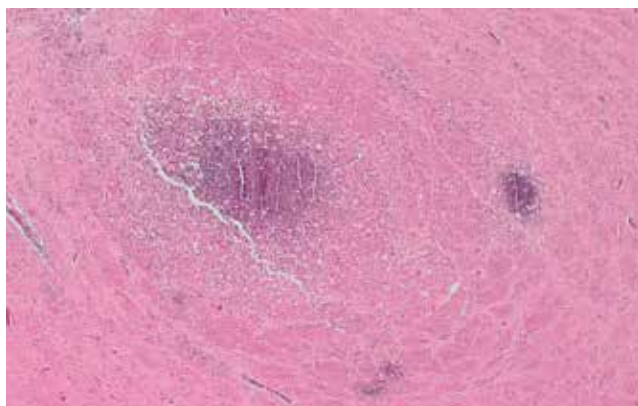
A one-year-old Charolais hogget was submitted to Limerick RVL. At grass, the animal had displayed poor thrive for a few weeks. It had become weakened and unable to rise in the last few days before death. No other deaths had occurred in the group. Abscessation of the myocardium, endocardium (valves)

and kidneys was disclosed at necropsy. Pulmonary congestion was also noted. *Staphylococcus aureus* was isolated by culture from the kidney, heart and liver.



**Figure 17: Renal (left) and (right) myocardial abscessation in a hogget from which *S. aureus* was cultured. Photo: Alan Johnson.**

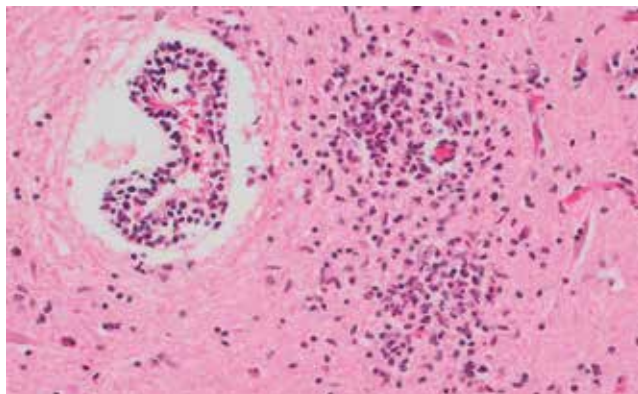
## NERVOUS SYSTEM



**Figure 18: Multifocal areas of microabscessation in the brain of a ewe, suggestive of listeriosis. Photo: Brian Toland.**

### Listeriosis

Kilkenny RVL examined a ewe with a history of sudden death. Histopathology of the brain disclosed a suppurative meningoencephalitis with microabscesses and perivascular lymphocyte cuffing, most severe in the hindbrain. These findings are suggestive of involvement of *Listeria sp.* most commonly *L. monocytogenes*.



**Figure 19: Microabscessation and perivascular cuffing suggestive of listeriosis. Photo: Brian Toland.**

## POISONINGS

### Plant poisoning

Athlone RVL examined three eight-month-old lambs with a history of sudden death after breaking out of the field where they were grazing. There were similar post-mortem findings in all three lambs. The rumen contents contained several plant leaves identified as ivy (*Hedera helix*), and laurel-like ornamental shrubs *Euonymus japonicus* and *Pieris japonicus*. There was marked pulmonary congestion and oedema, haemorrhages on the epicardial surface and froth in the trachea. There were multifocal/segmental serosal haemorrhages along the small and large intestines of one of the lambs. A diagnosis of plant poisoning was reached with *E. japonicus* and *P. japonicus* identified as the toxic plants involved.

Poisoning incidents in sheep can arise when sheep break out into gardens and tend to increase over the winter months, possibly when grazing is limited. *Pieris* species are very toxic to both animals and humans due to grayanotoxins that bind to sodium channels of cardiac and skeletal muscle and nerve cells. The toxic dose of fresh leaves is reported to be 0.1-0.6 per cent of bodyweight for ruminants, equating to around 30-180g of fresh leaves for a 30kg lamb. The symptoms of *E. japonicus* poisoning occur eight to 15 hours after intake and include vomiting, abdominal pain, inflammation of the intestines, severe, slimy, watery or bloody diarrhoea, disturbances of circulation, collapse and coma. Most farmers are unaware that ivy is mildly toxic to ruminants, but to a much lesser degree than the other plants detected, and animals rarely consume enough to do any more harm than a mild, self-limiting diarrhoea.

## MISCELLANEOUS

### Hypomagnesaemia (grass tetany)

Athlone RVL examined a five-year-old ewe with a history of sudden death. There had been 10 similar losses in the flock. On necropsy, there were multifocal petechial haemorrhages on the epicardium. There were no other significant gross lesions reported. A sample of vitreous humour was collected for analysis. The concentration of magnesium in the vitreous humour was 0.36mmol/L. Vitreous humour magnesium concentration in adult sheep of  $\leq 0.65$ mmol/L (or aqueous humour concentration  $< 0.33$ mmol/L) for up to 24 hours post-mortem is associated with severe hypomagnesaemia and tetany. A diagnosis of hypomagnesaemia/grass tetany was made, and a review of grass tetany control was recommended.

### Neoplasia

A four-year-old ewe with a history of slowly fading over a number of weeks after lambing was submitted to Sligo RVL. The farmer reported three similar deaths. On necropsy, the ewe was emaciated, anaemic and dehydrated. There were diffuse abdominal fibrous adhesions centred around a firm peri-jejunal mass that appeared neoplastic in nature. Histopathology of the mass was typical of adenocarcinoma. Neoplasia can be observed sporadically in sheep, and it is

unlikely that the other deaths on farm were caused by similar lesions. Other causes should be considered more likely and if further cases occurred, further submission would be necessary to establish if there was an underlying issue in the flock.

## OTHER SPECIES

### Dystocia

A nine-year-old mare was submitted to Limerick RVL with a history of prolapse and bleeding. There was a vaginal prolapse, resulting in a tear of the vagina through which two metres of colon had herniated. The cervix was open and the foal palpable through the cervix. There were blood clots and frank blood in the abdominal cavity. A diagnosis of vaginal prolapse and rupture during foaling was made.